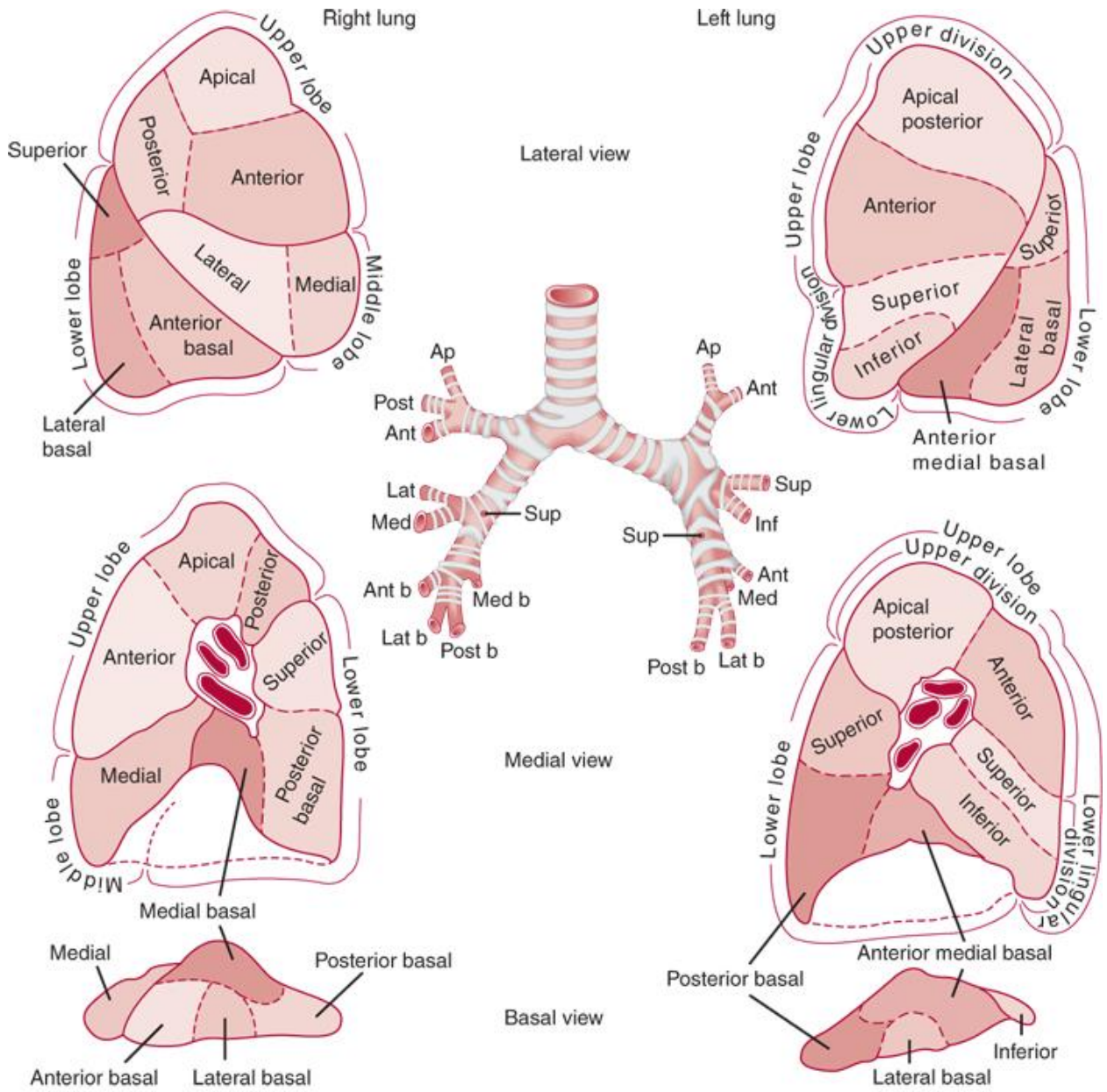
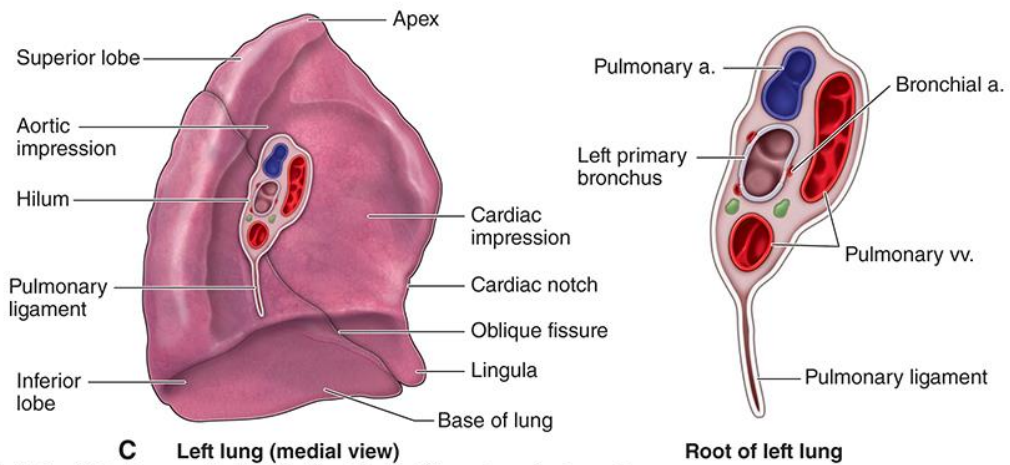
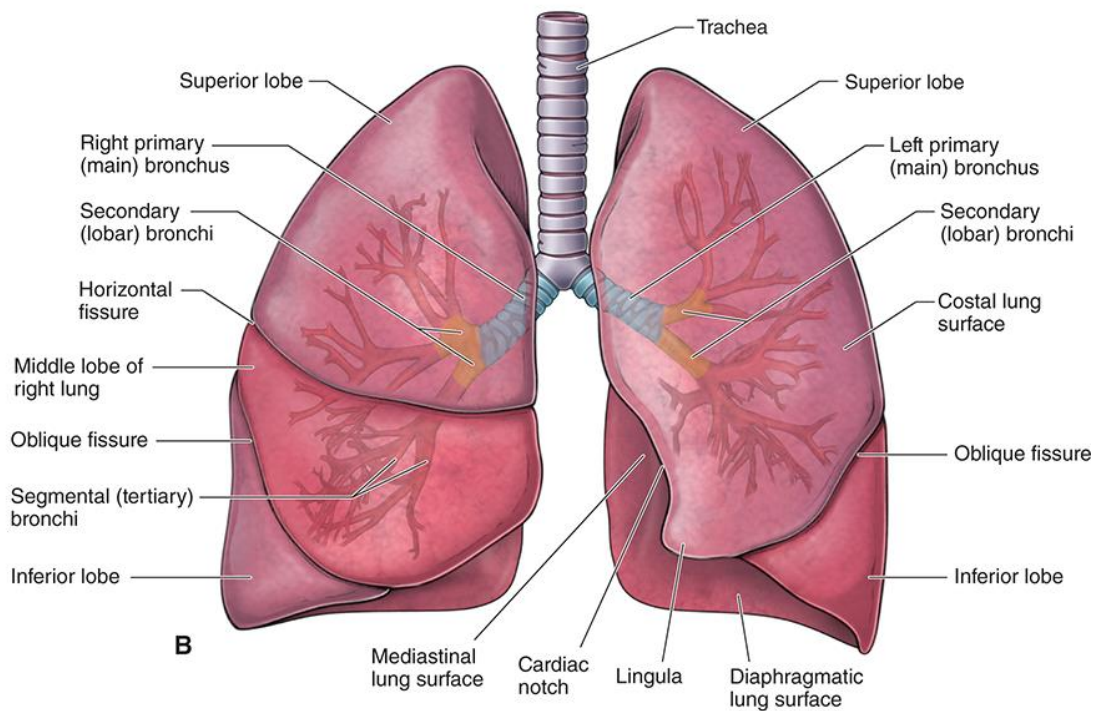
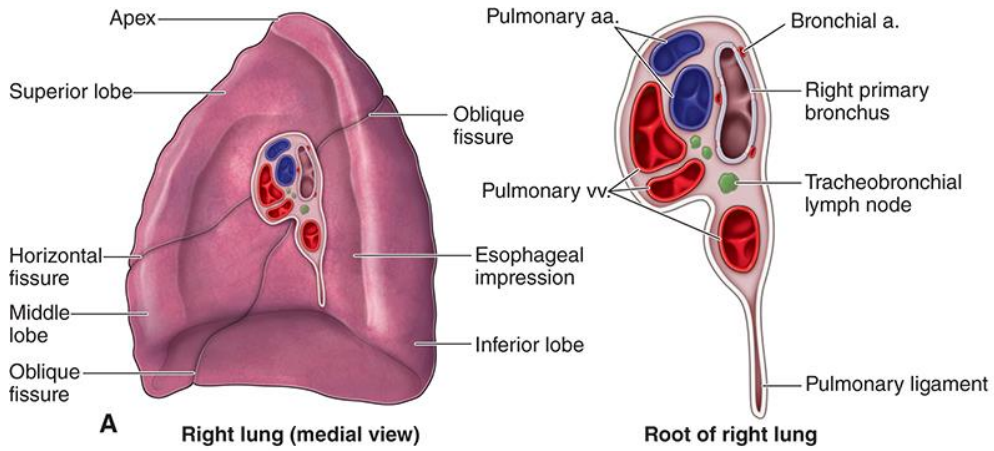


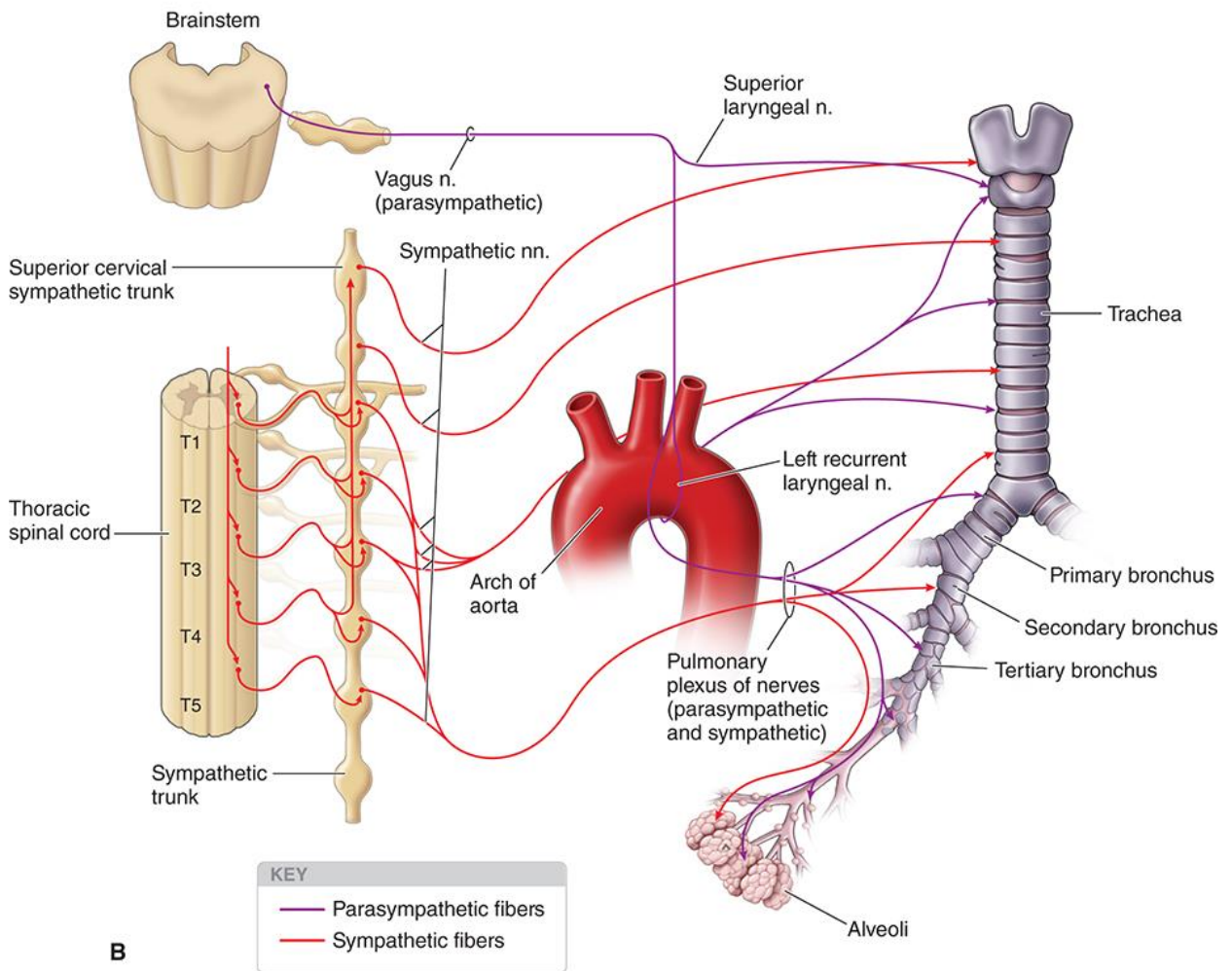
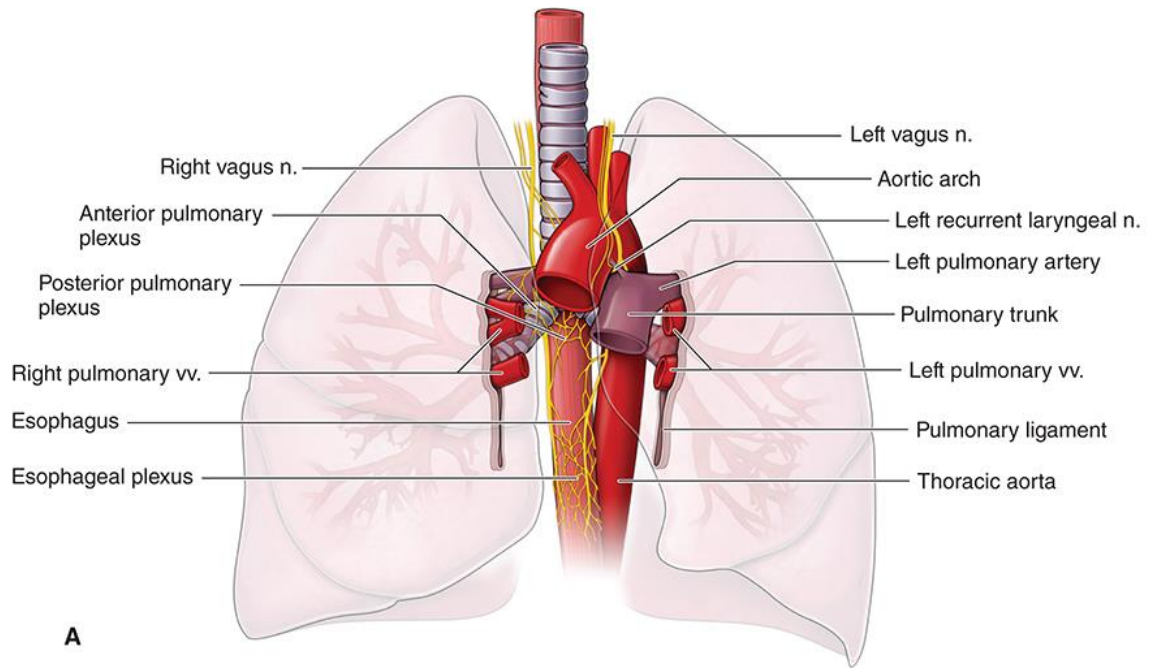
KVĚPAVIMO SISTEMA





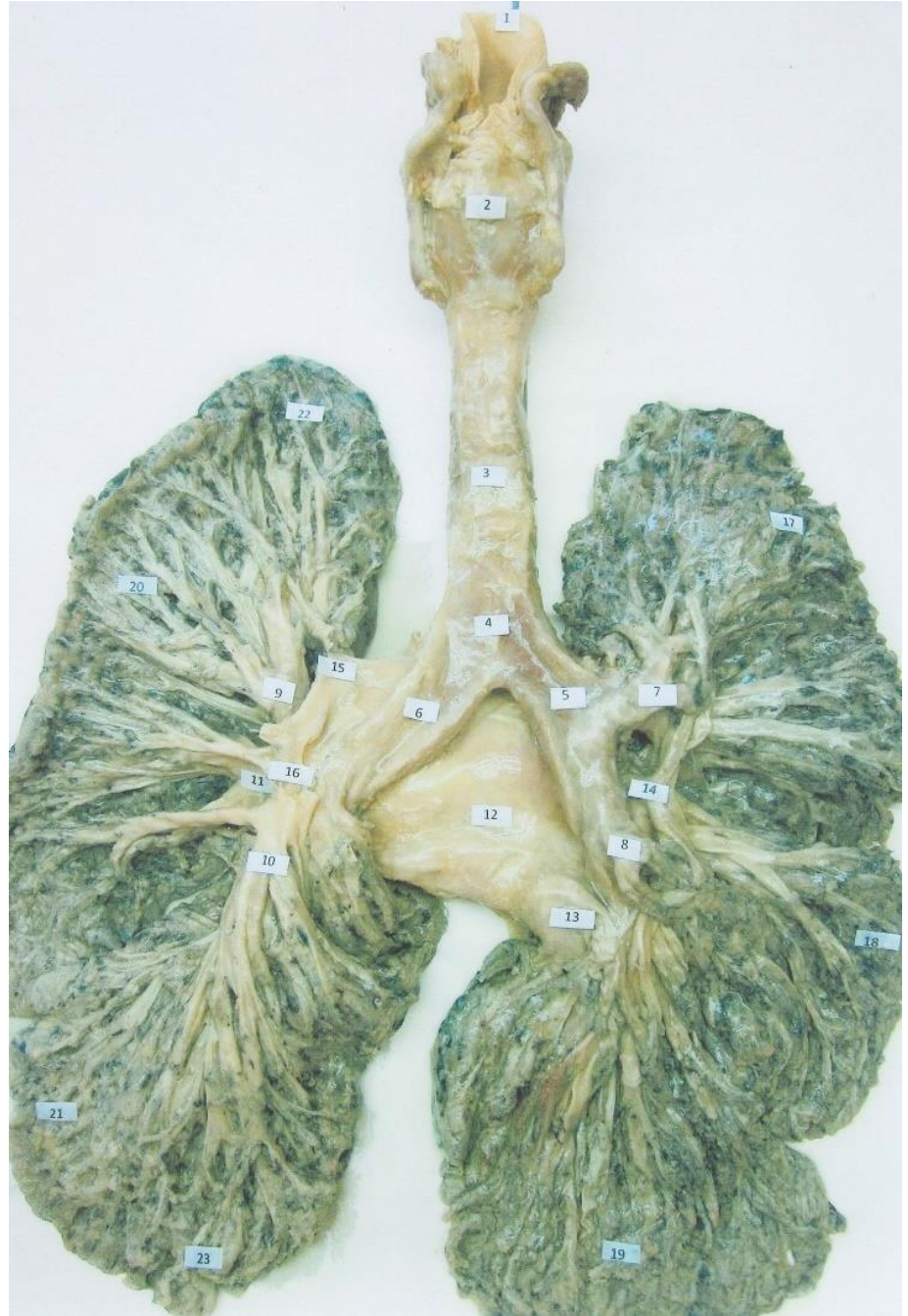
Source: Gerard M. Doherty: Current Diagnosis & Treatment: Surgery, 14th Edition
 www.accessmedicine.com
 Copyright © McGraw-Hill Education. All rights reserved.



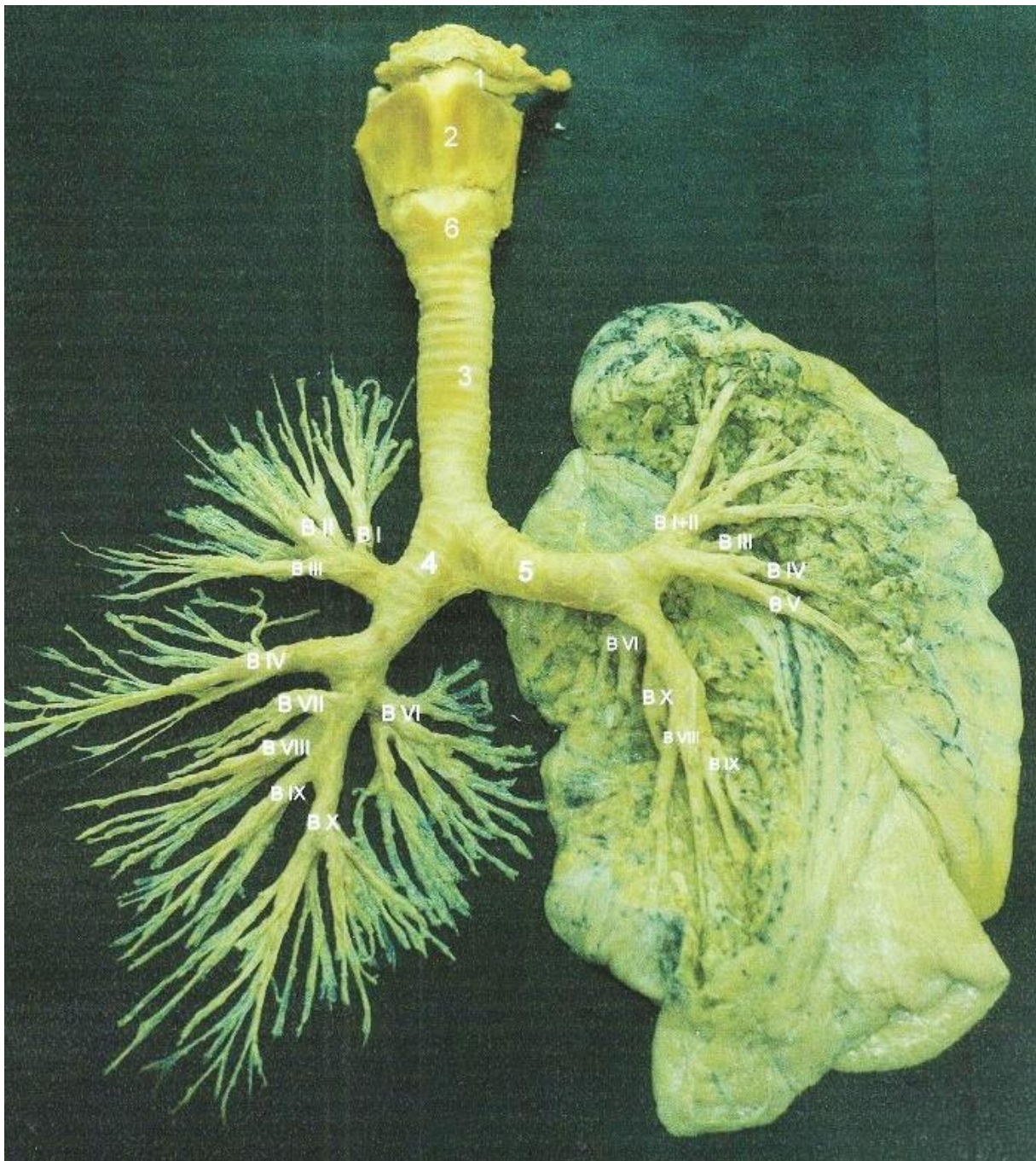


Source: David A. Morton, K. Bo Foreman, Kurt H. Albertine: *The Big Picture: Gross Anatomy, 2E*
 Copyright © McGraw-Hill Education. All rights reserved.

1. Epiglottis
2. Cartilage thyroidea
3. Trachea
4. Bifurcation tracheae
5. Bronchus principalis dexter
6. Bronchus principalis sinister
7. Bronchus lobaris superior dexter
8. Bronchus lobaris inferior dexter
9. Bronchus lobaris superior sinister
10. A. pulmonalis
11. A. pulmonalis sinistra inferior
12. Pericardium
13. V. pulmonalis dextra inferior
14. Aa. Lobares superiores pulmonis dextri
15. V. pulmonalis sinistra superior
16. A. pulmonalis sinistra
17. Lobus superior pulmonis dexter
18. Lobus medius pulmonis dexter
19. Lobus inferior pulmonis dexter
20. Lobus superior pulmonis sinister
21. Lobus inferior pulmonis sinister
22. Apex pulmonis
23. Basis pulmonis



Darbą atliko: LSMU Saulė Kiaunytė, Dovilė Bendinskaitė, Goda Šlekytė, 2011m.
 Redagavo: LSMU MF 5k, 20gr, Anatomijos instituto Prozektore Orinta Klimaitė

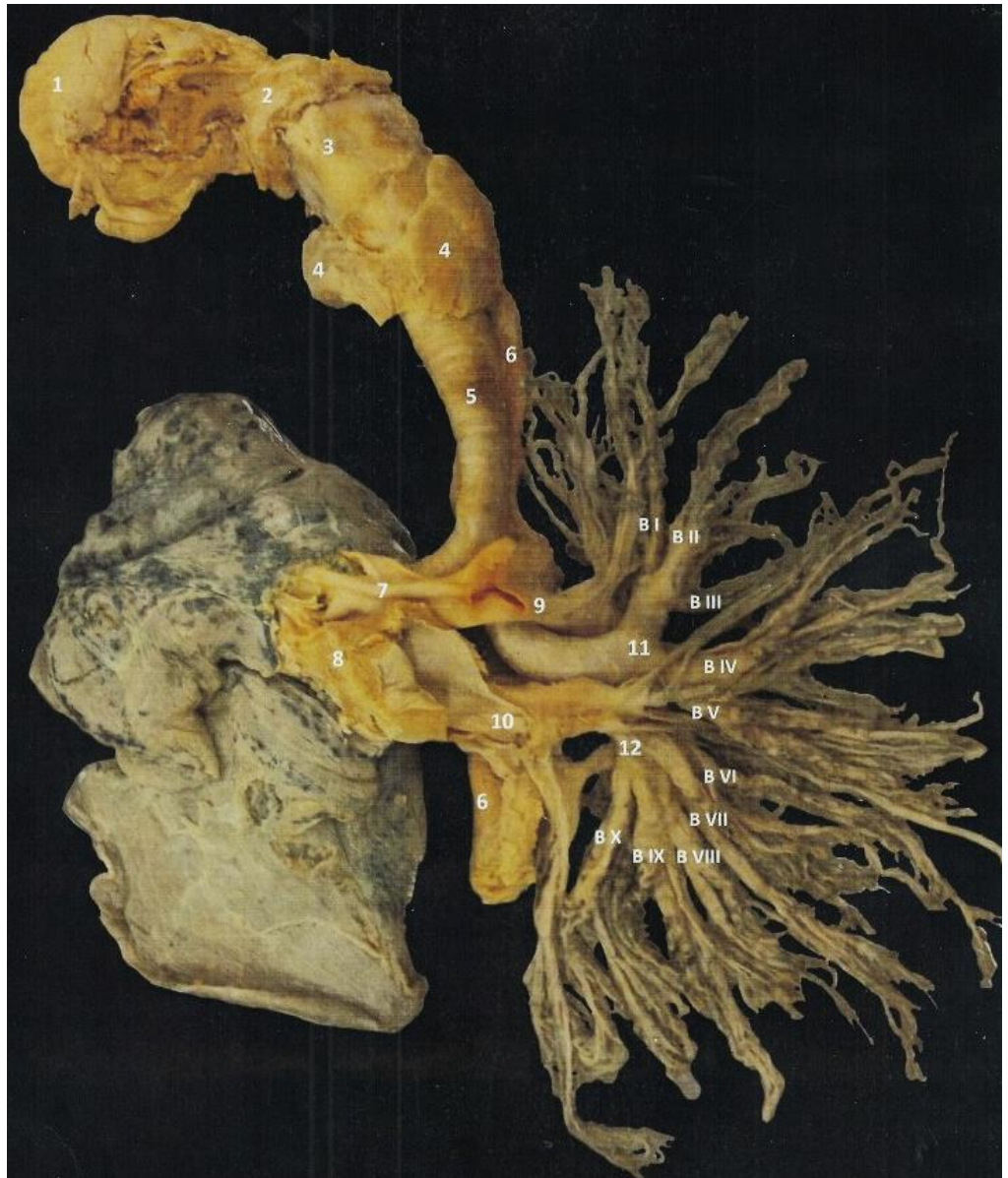

1. Os hyoideum
2. Larynx, cartilage thyroidea
3. Trachea
4. Bronchus principalis dexter
 - Bronchus lobaris superior dexter
 - B I – Bronchus segmentalis apicalis

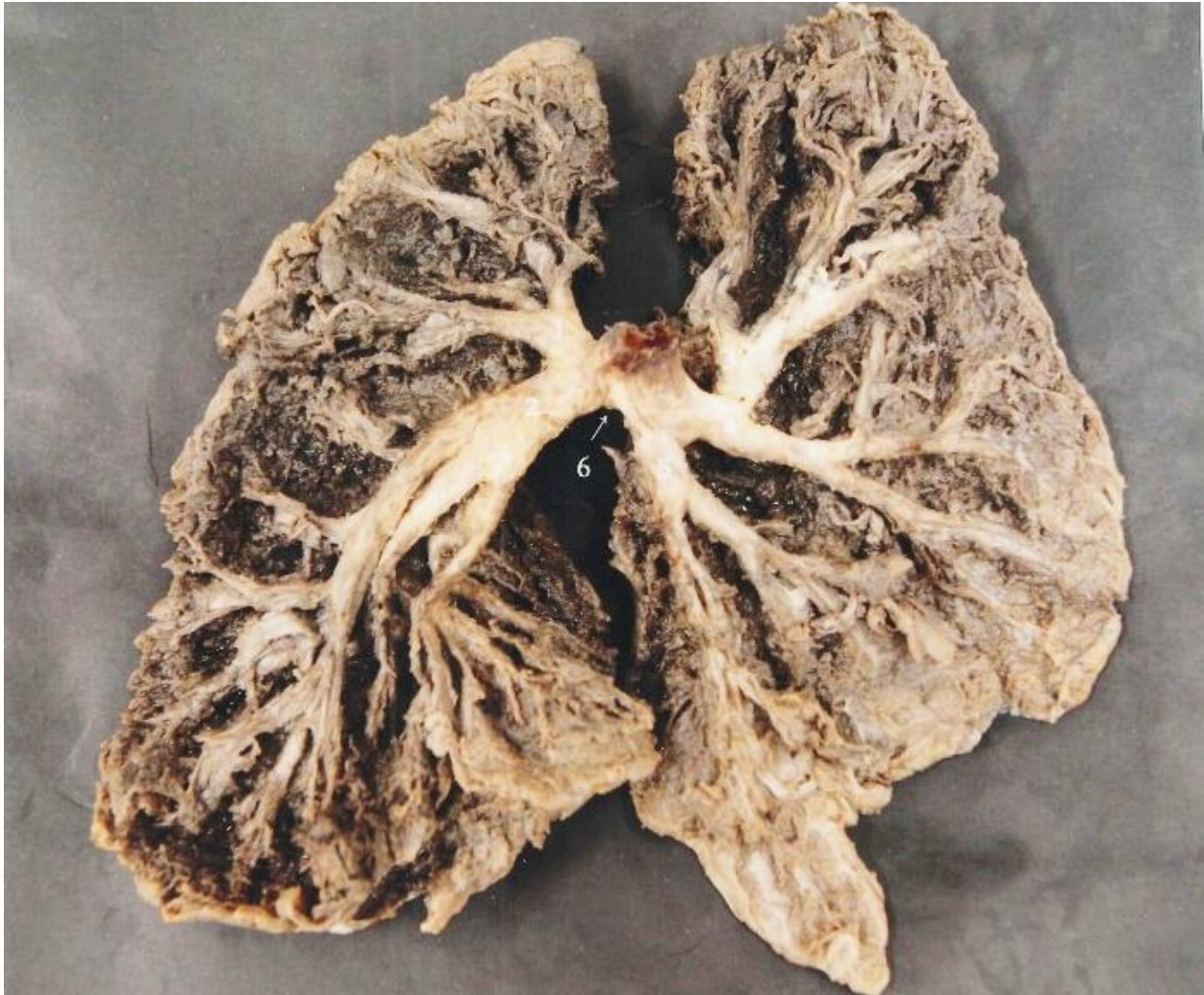
- B II – Bronchus segmentalis posterior
- B III – Bronchus segmentalis anterior
- Bronchus lobaris medius dexter
- B IV – Bronchus segmentalis lateralis

- B V – Bronchus segmentalis medialis
- Bronchus lobaris inferior dexter
- B VI – Bronchus segmentalis superior
- B VII – Bronchus segmentalis basalis anterior
- B IX – Bronchus segmentalis basalis lateralis
- B X – Bronchus segmentalis basalis posterior
- 5. Bronchus principalis sinister
 - Bronchus lobaris superior sinister
 - B I + II – Bronchus segmentalis apicoposterior
- B III – bronchus segmentalis anterior
- B IV – Bronchus lingularis superior
- B V – Bronchus lingularis inferior
- Bronchus lobaris inferior sinister
- B VI – Bronchus segmentalis superior
- B VIII – Bronchus segmentalis basalis lateralis
- B IX – Bronchus segmentalis balalis lateralis
- B X – Bronchus segmentalis basalis posterior
- 6. Larinx, cartilage cricoidea

1. lingua
2. Os hyoideum
3. Cartilage thyreoidea
4. Glandula thyreoidea
5. Trachea
6. Oesophagus
7. A. pulmonalis dextra
8. V. pulmonalis dextra
9. A. pulmonalis sinistra
10. V. pulmonalis sinistra
11. Bronchus lobaris superior sinister
 - B I – bronchus segmentalis apicalis
 - B II – bronchus segmentalis posterior
 - B III – bronchus segmentalis anterior
 - B IV – bronchus segmentalis superior
 - B V - bronchus segmentalis inferior
12. Bronchus lobaris inferior sinister
 - B VI – Bronchus segmentalis superior
 - B VII – Bronchus segmentalis basalis medialis
 - B VIII – Bronchus segmentalis basalis anterior
 - B IX – Bronchus segmentalis basalis lateralis
 - B X - Bronchus segmentalis basalis posterior



Darbą atliko: LSMU MF 1k, 21gr Gabrielė Šileikaitė ir Emilis Zavickas
 Redagavo: LSMU MF 5k, 20gr, Anatomijos instituto Prozektore Orinta Klimaitė



1. Bronchus lobaris superior sinister
2. Bronchus lobaris inferior sinister
3. Bronchus lobaris superior dexter
4. Bronchus lobaris medius dexter
5. Bronchus lobaris inferior dexter
6. Bifurcatio tracheae

Redagavo: LSMU MF 5k, 20gr, Anatomijos instituto Prozektorė Orinta Klimaitė