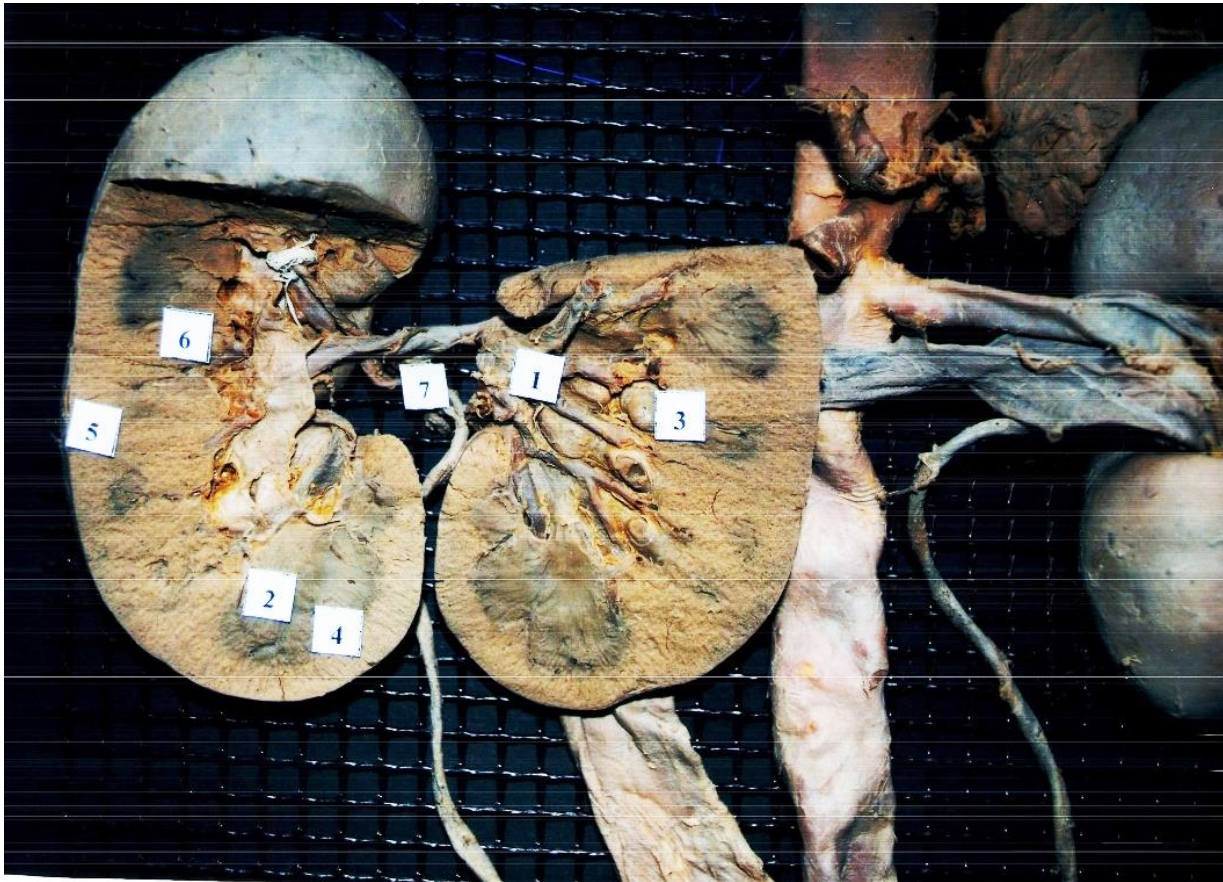


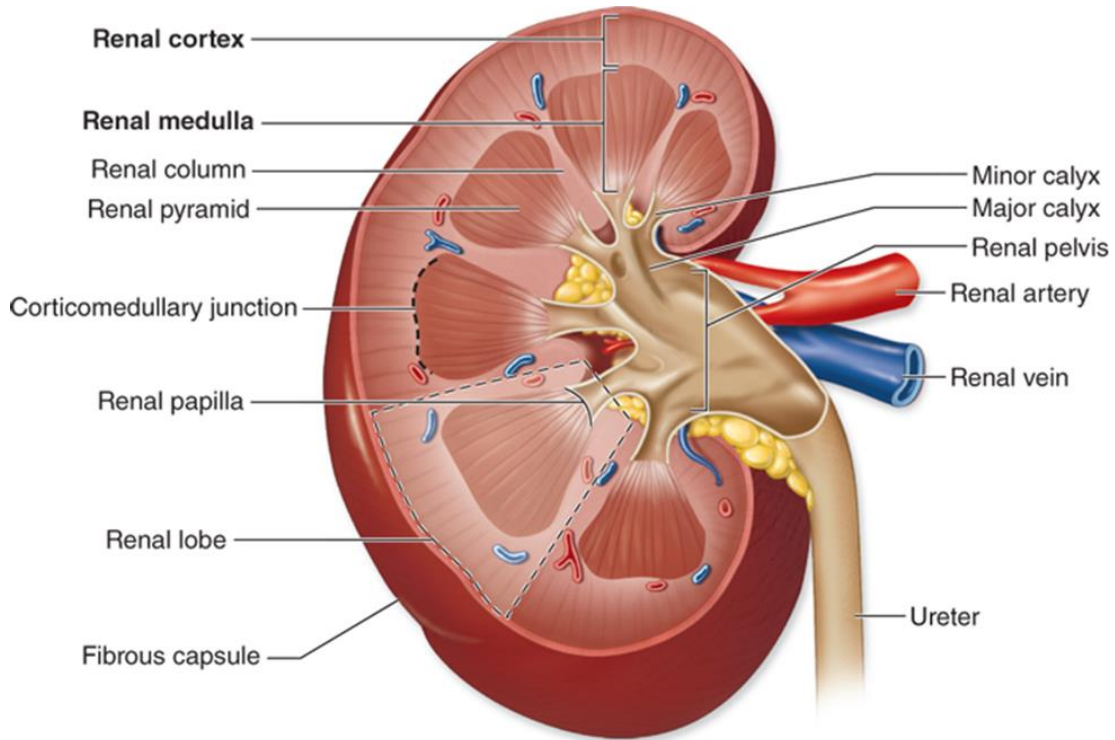
# ŠLAMPIMO SISTEMOS ORGANAI



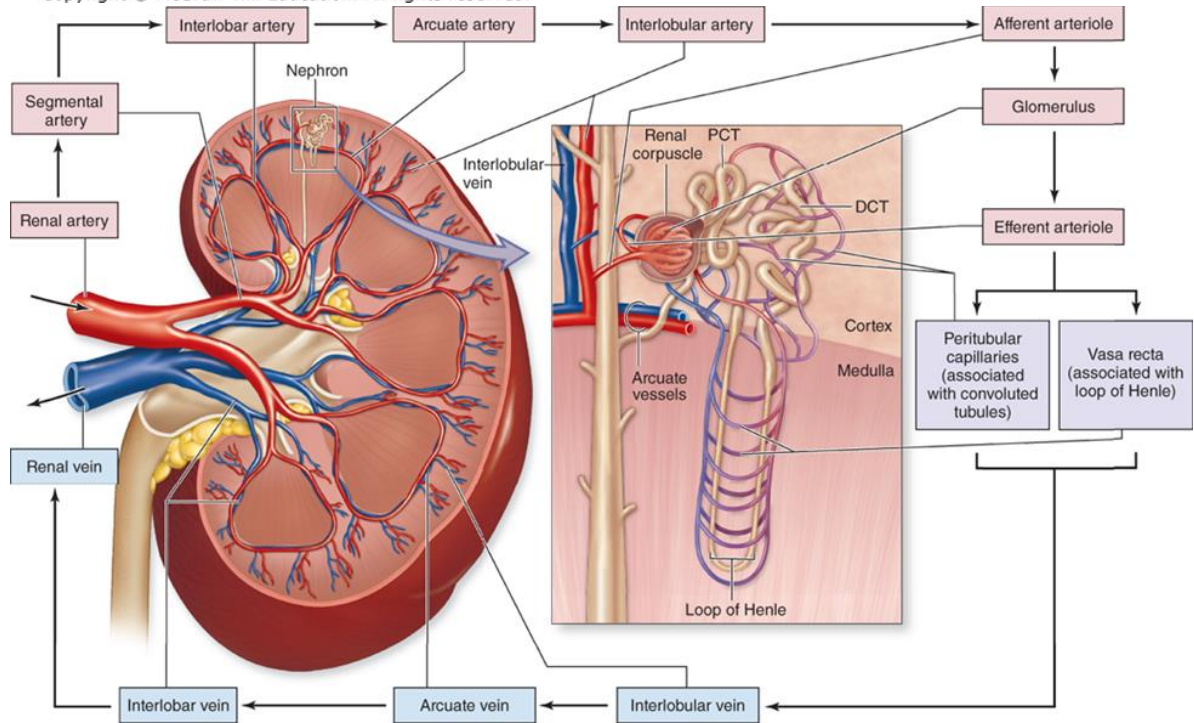
## INKSTAS (ren)



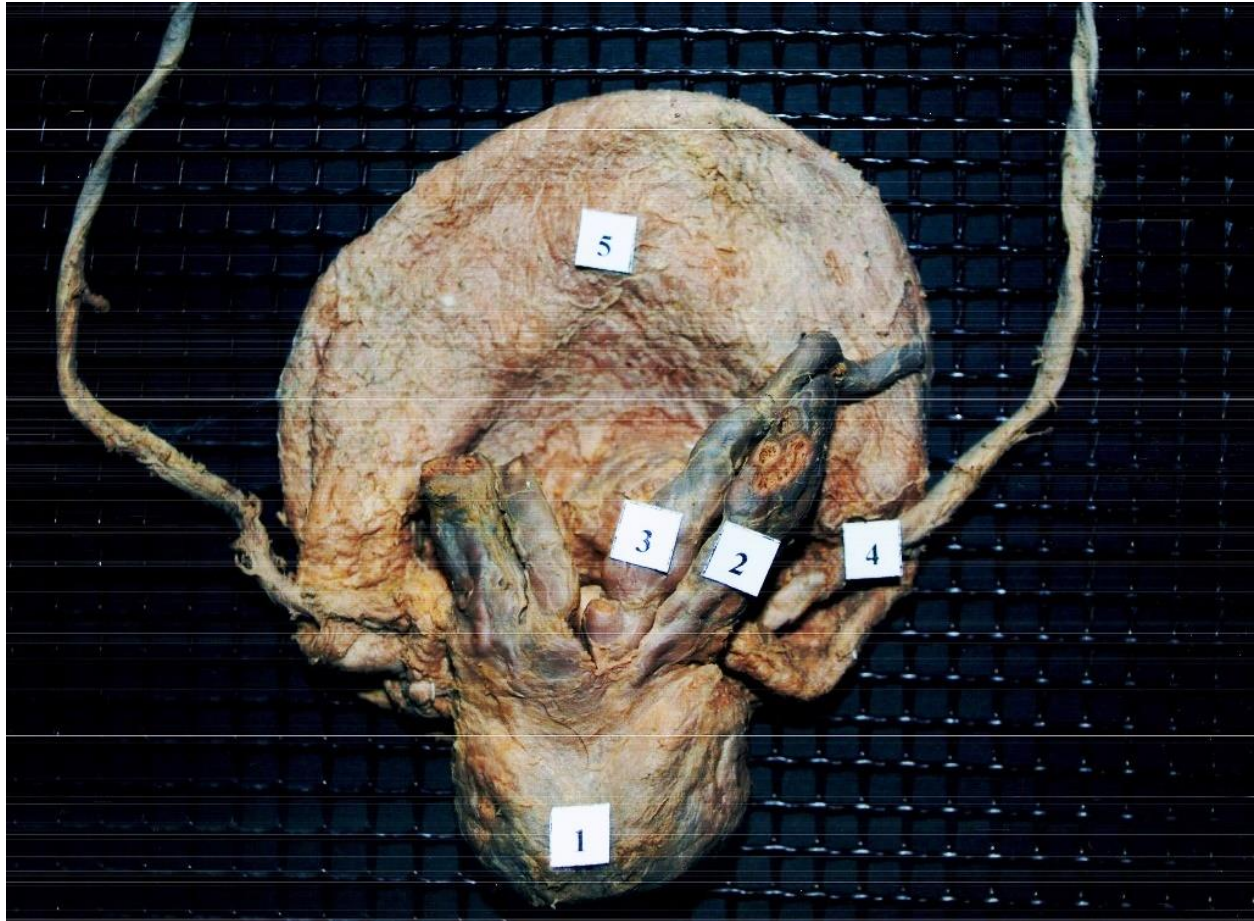
1. Arteria segmentalis
2. Pyramis renalis
3. Papilla renalis
4. Basis pyramidis renalis
5. Cortex
6. Columna renalis
7. Ureter



Source: Anthony L. Mescher: Junqueira's Basic  
 Histology: Text and Atlas, 15th Edition.  
 Copyright © McGraw-Hill Education. All rights reserved.



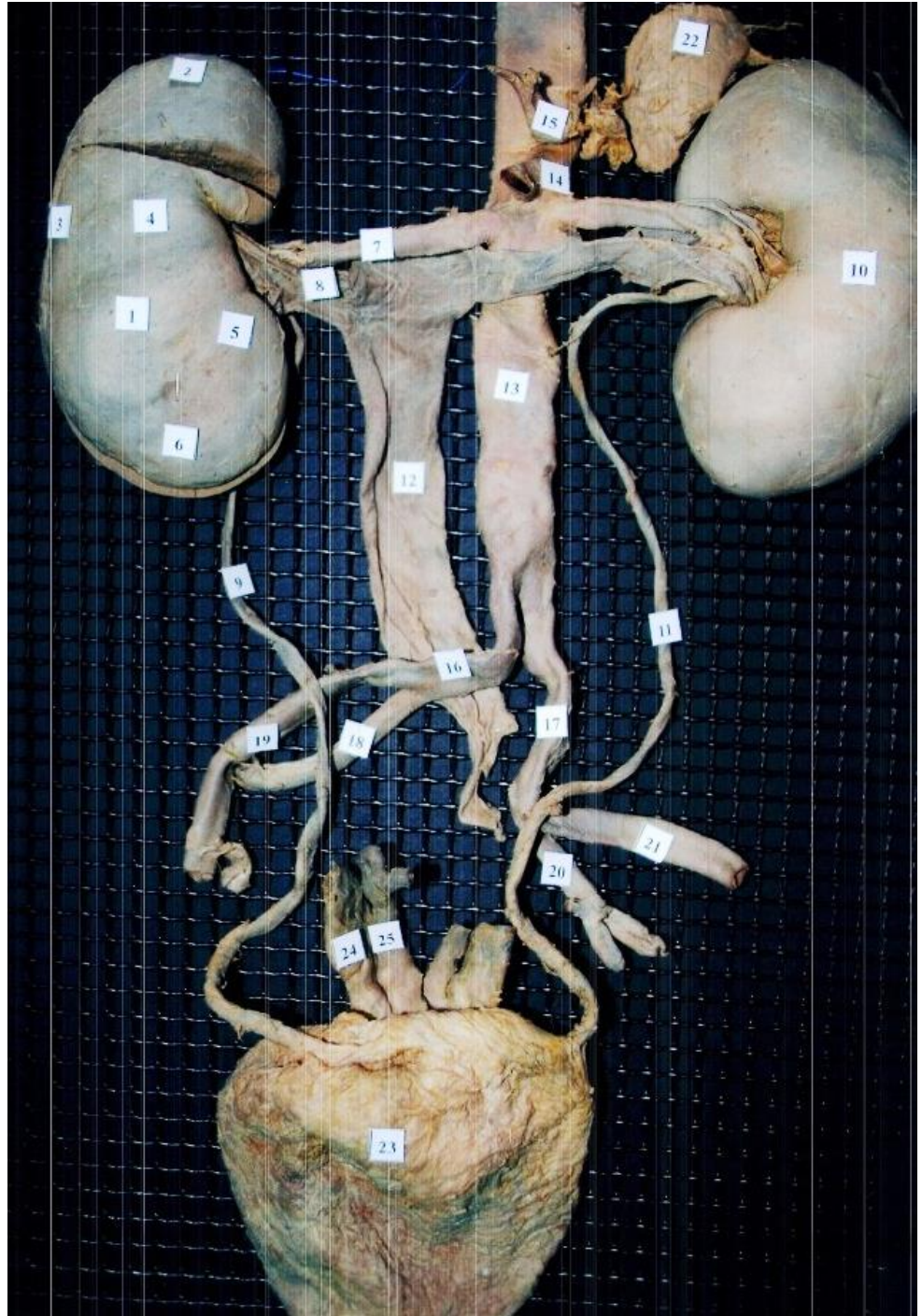
Source: Anthony L. Mescher: Junqueira's Basic  
 Histology: Text and Atlas, 15th Edition.  
 Copyright © McGraw-Hill Education. All rights reserved.



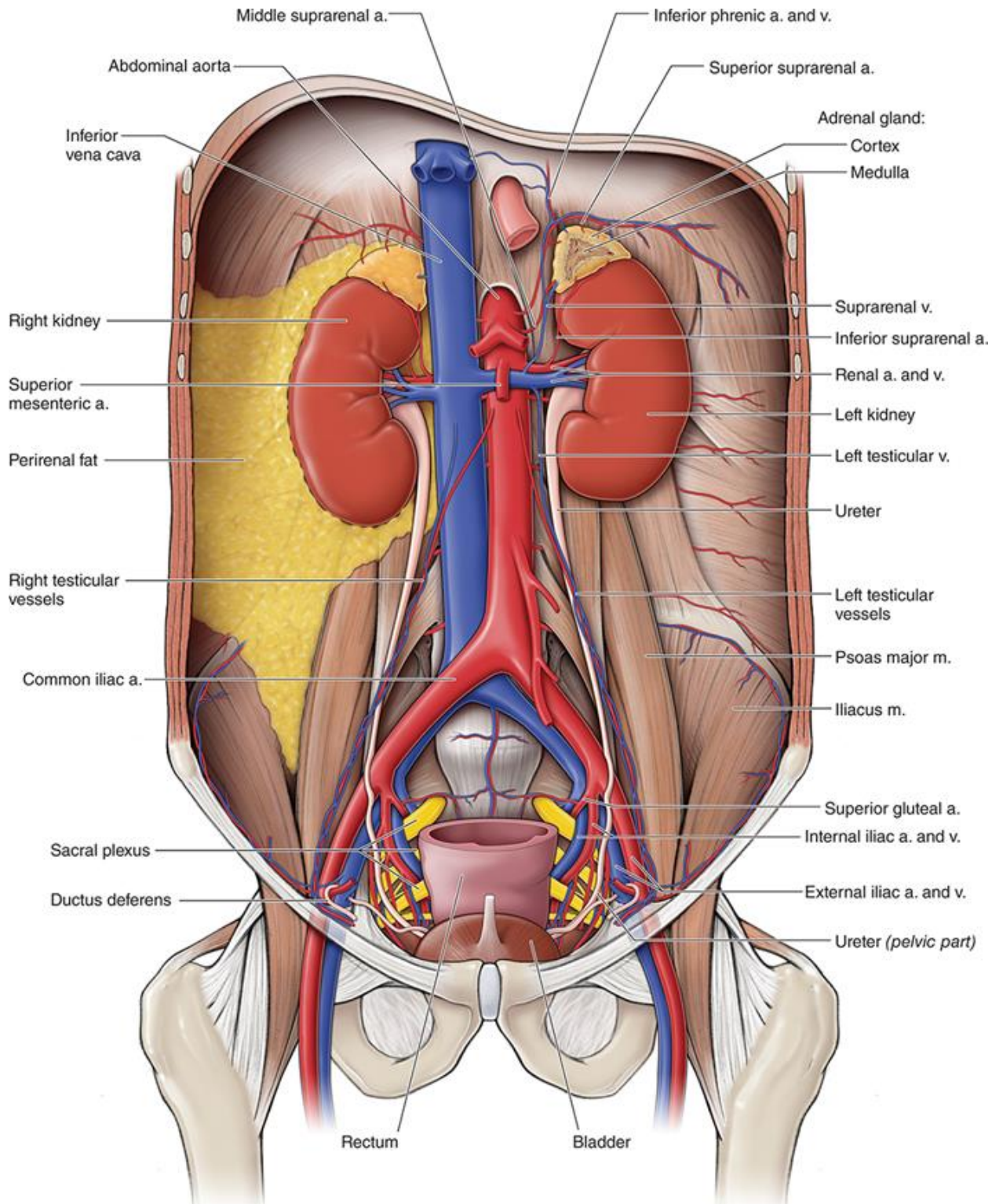
1. Prostata
2. Vesiculus seminalis
3. Ductus deferens
4. Ureter
5. Vesica urinaria

Redagavo: LSMU MF 5k, 20gr, Anatomijos instituto Prozektore Orinta Klimaitė

1. Ren dexter
2. Extremitas superior
3. Margo lateralis
4. Margo lateralis
5. Facies anterior
6. Margo medialis
7. Arteria renalis
8. Vena renalis
9. Ureter dexter
10. Ren sinister
11. Ureter sinister
12. Vena cava onferior
13. Aorta abdomoinalis
14. Arteria mesenterica superior
15. Truncus coeliacus
16. Arteria iliaca communis dexter
17. Arteria iliaca communis sinister
18. Arteria iliaca posterior dextra
19. Arteria iliaca anterior dexter
20. Arteria iliaca posterior sinistra
21. Arteria iliaca anterior sisnitra
22. Glandula suprarenalis
23. Vesica urinaria
24. Vesicula seminalis
25. Ductus deferens

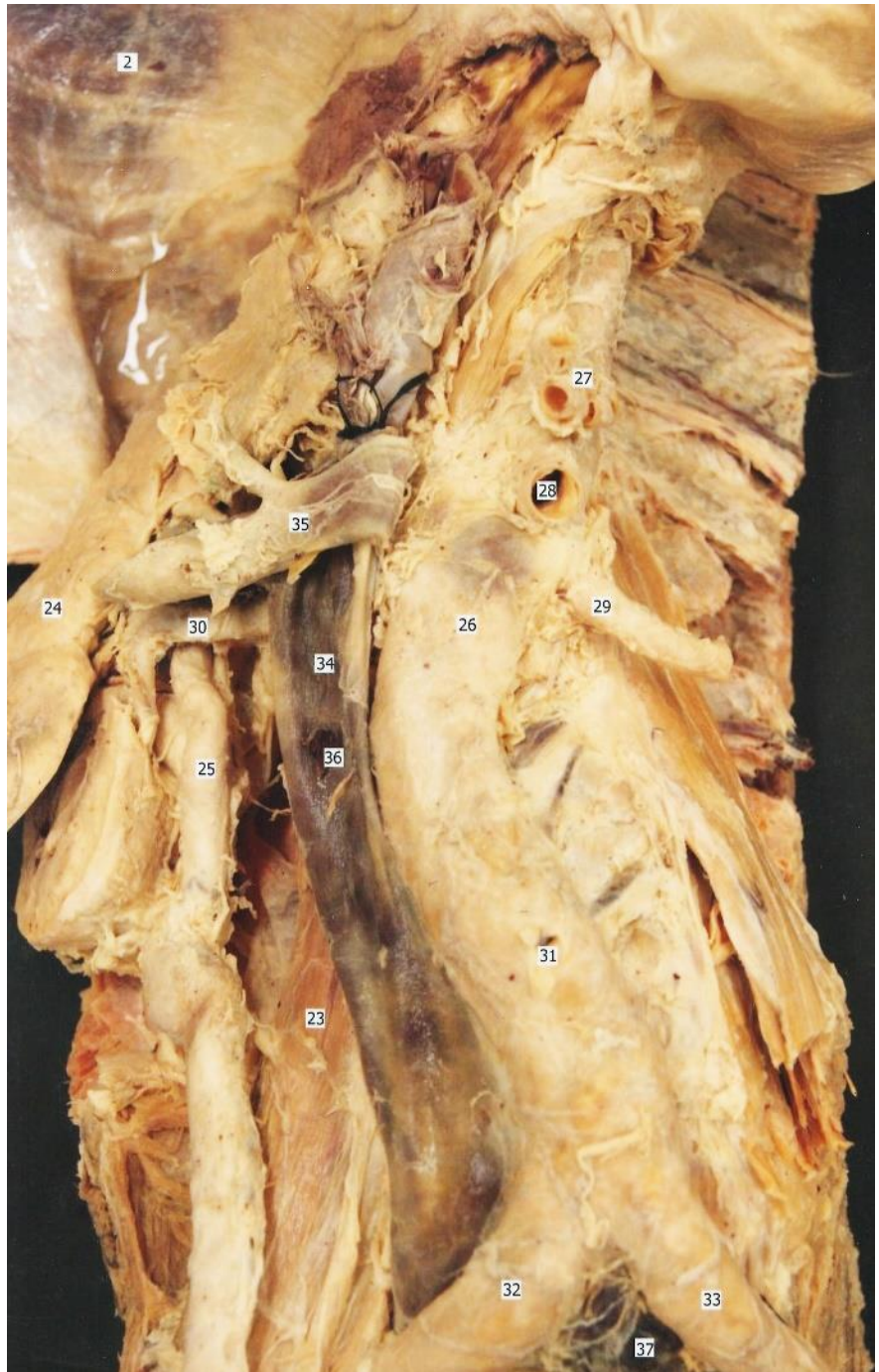


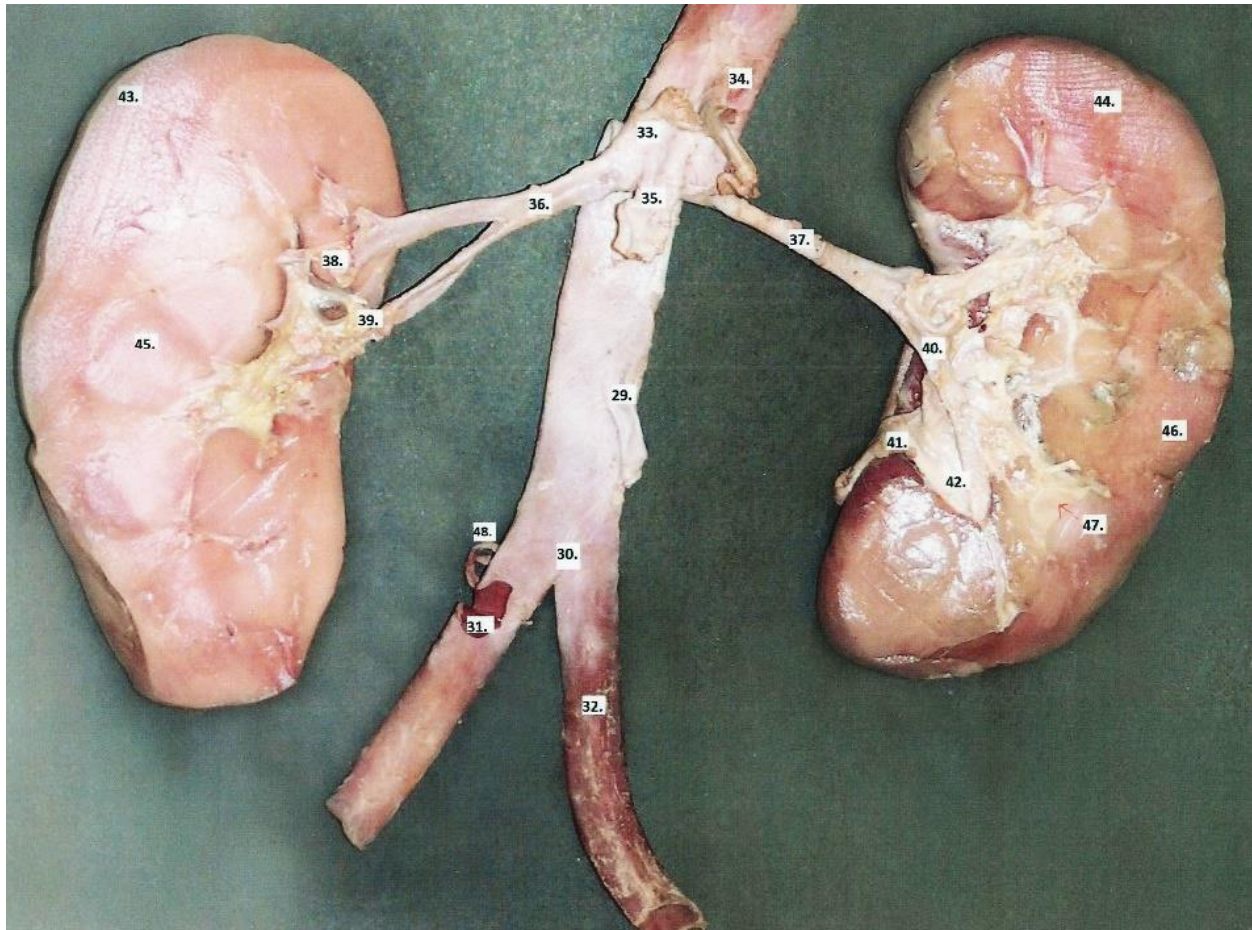
Redagavo: LSMU MF 5k, 20gr, Anatomijos instituto Prozektore Orinta Klimaitė



Source: David A. Morton, K. Bo Foreman, Kurt H. Albertine: *The Big Picture: Gross Anatomy*, 2e  
 Copyright © McGraw-Hill Education. All rights reserved.

- 23. Musculus psoas major
- 24. Ren
- 25. Ureter
- 26. Aorta abdominalis
- 27. Truncus coeliacus
- 28. Arteria mesenterica superior
- 29. Arteria renalis sinistra
- 30. Arteria renalis dextra
- 31. Arteria mesenterica inferior
- 32. Arteria iliaca communis dextra
- 33. Arteria iliaca communis sinistra
- 34. Vena cava inferior
- 35. Vena renalis dextra
- 36. Vena testicularis
- 37. Vena iliaca communis sinistra

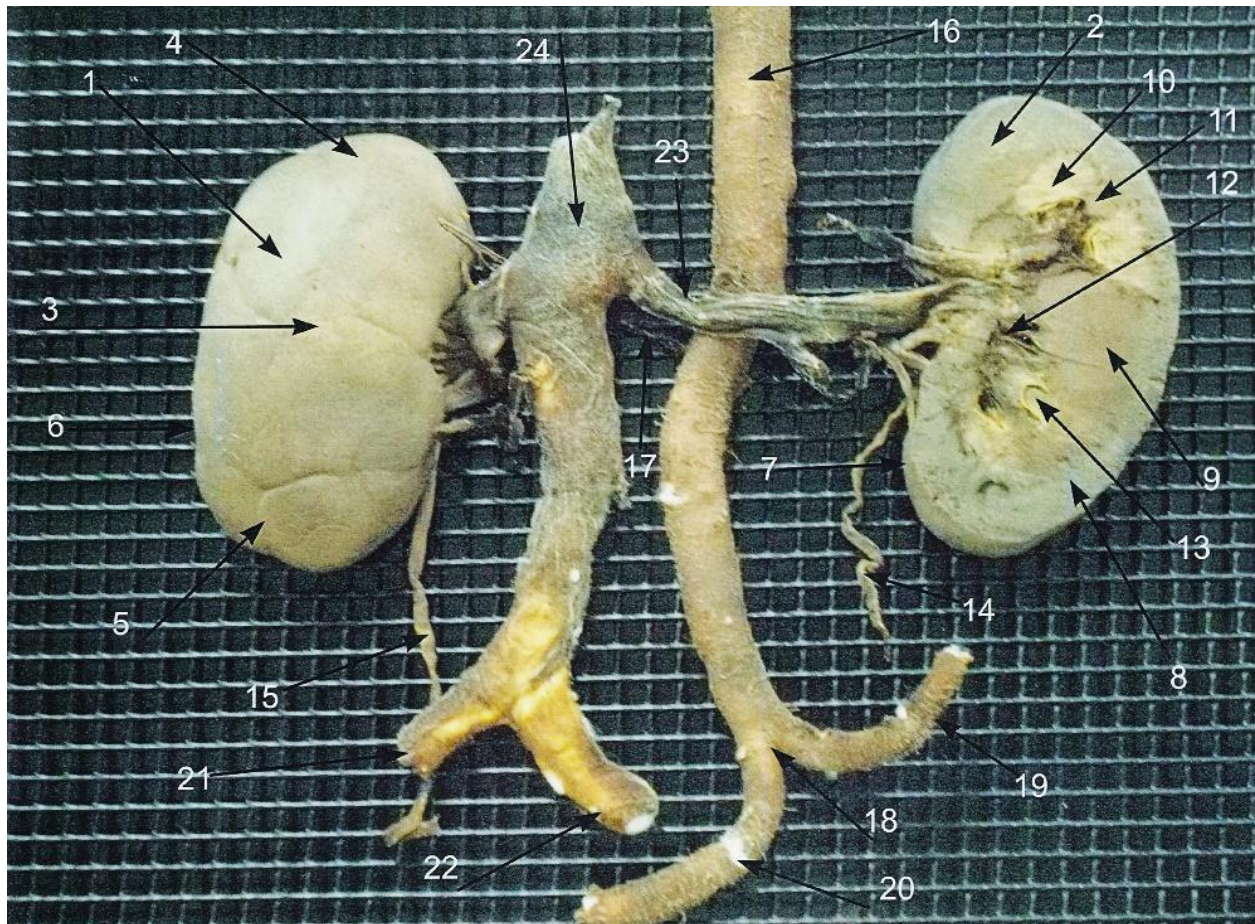




- |                                 |                                  |
|---------------------------------|----------------------------------|
| 29. A. mesenterica inferior     | 39. A. renalis inferioris dextra |
| 30. Bifurcatio aortae           | 40. A. renalis sinistra          |
| 31. A. iliaca communis dextra   | 41. Ureter sinister              |
| 32. A. iliaca communis sinistra | 42. Pelvis renalis               |
| 33. A. supra renalis            | 43. Capsula fibrosa              |
| 34. Truncus coeliacus           | 44. Ren sinister                 |
| 35. A. mesenterica superior     | 45. Ren dexter                   |
| 36. A. renalis dextra           | 46. Cortex renalis               |
| 37. A. renalis sinistra         | 47. Medulla renalis              |
| 38. A. renalis dextra           | 48. A. sacralis mediana          |

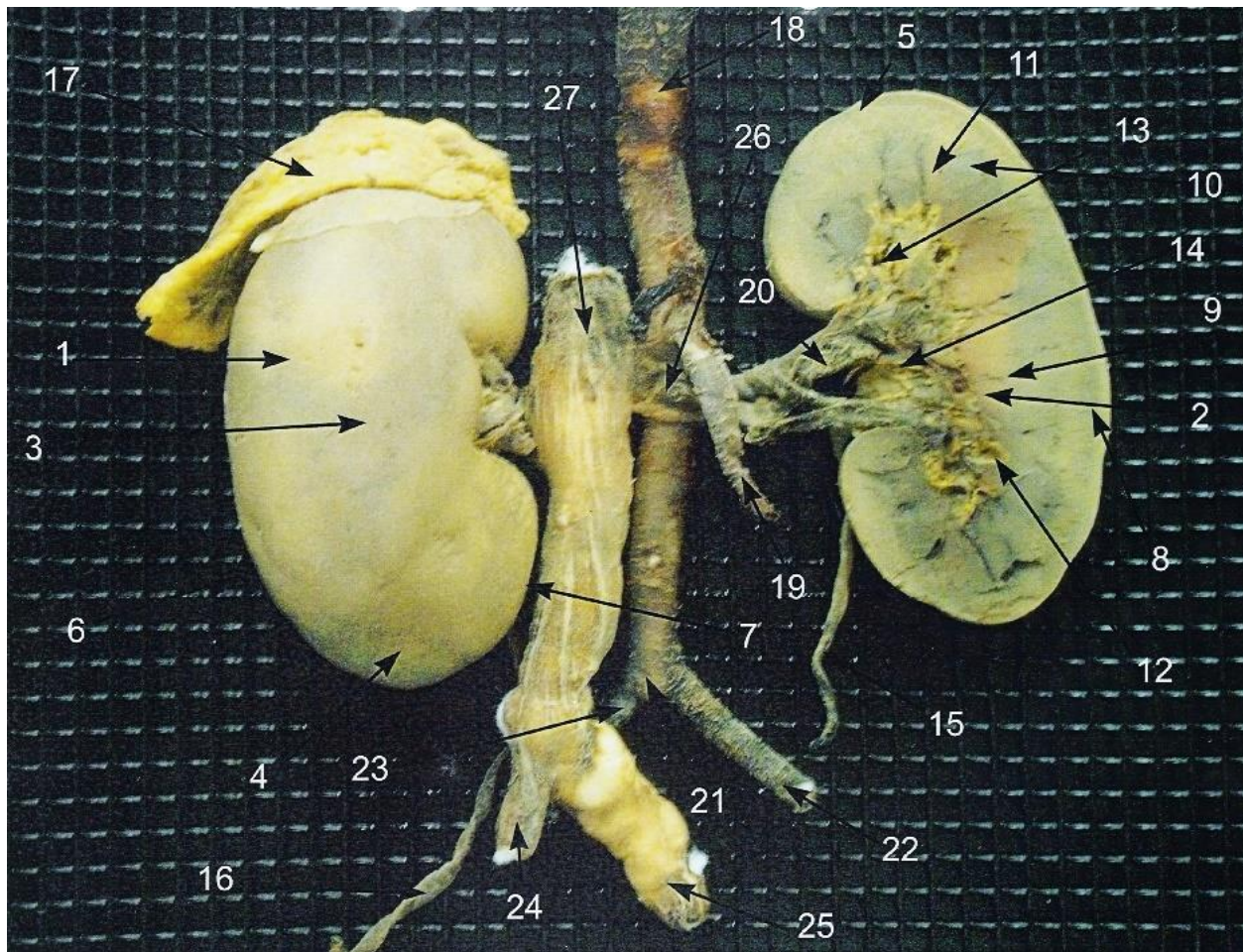
Darbą atliko: LSMU OF 1k. Darius Vaičius ir Nerijus Zakas, 2011-2012m.m.  
 Redagavo: LSMU MF 5k, 20gr, Anatomijos instituto Prozektore Orinta Klimaitė





- |                        |                                      |
|------------------------|--------------------------------------|
| 1. Ren dexter          | 13. Sinus renalis                    |
| 2. Ren sinister        | 14. Ureter sinister                  |
| 3. Facies anterior     | 15. Ureter dexter                    |
| 4. Extremitas superior | 16. Aorta abdominalis                |
| 5. Extremitas inferior | 17. Arteria renalis dextra           |
| 6. Margo lateralis     | 18. Bifurcatio aortae                |
| 7. Margo medialis      | 19. Arteria iliaca communis sinistra |
| 8. Cortex renalis      | 20. Arteria iliaca communis dextra   |
| 9. Medulla renalis     | 21. Vena iliaca communis dextra      |
| 10. Pyramis renalis    | 22. Vena iliaca communis sinistra    |
| 11. Columna renalis    | 23. Vena renalis sinistra            |
| 12. Pelvis renalis     | 24. Vena cava inferior               |

Darba atliko: LSMU MF 1k, 26gr Artūras Jacinavičius, Andrius Kotkis, 2012-2013m.m.  
 Redagavo: LSMU MF 5k, 20gr, Anatomijos instituto Prozektore Orinta Klimaitė

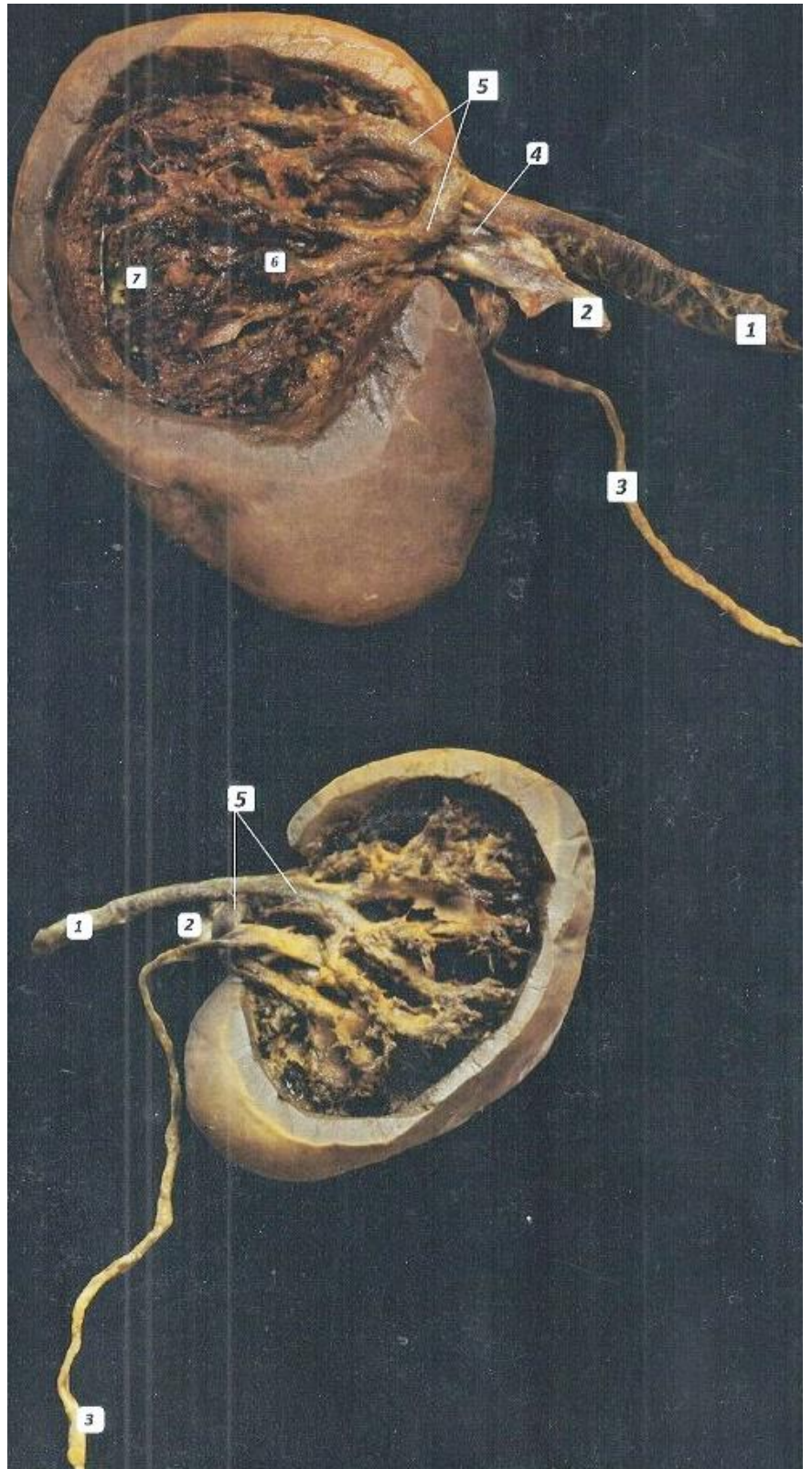


- |                        |                                      |
|------------------------|--------------------------------------|
| 1. Ren dexter          | 15. Ureter dexter                    |
| 2. Ren sinister        | 16. Ureter sinister                  |
| 3. Facies anterior     | 17. Glandula suprarenalis dextra     |
| 4. Extremitas superior | 18. Aorta abdominalis                |
| 5. Extremitas inferior | 19. Arteria mesenterica inferior     |
| 6. Margo lateralis     | 20. Arteria renalis sinistra         |
| 7. Margo medialis      | 21. Bifurcatio aortae                |
| 8. Cortex renalis      | 22. Arteria iliaca communis sinistra |
| 9. Medulla renalis     | 23. Arteria iliaca communis dextra   |
| 10. Pyramis renalis    | 24. Vena iliaca communis dextra      |
| 11. Columna renalis    | 25. Vena iliaca communis sinistra    |
| 12. Calyx renalis      | 26. Vena renalis sinistra            |
| 13. Sinus renalis      | 27. Vena cava inferior               |
| 14. Pelvis renalis     |                                      |

Darbą atliko: LSMU MF 1k 26gr, Artūras Jacinavičius, Andrius Kotkis, 2012-2013m.m.

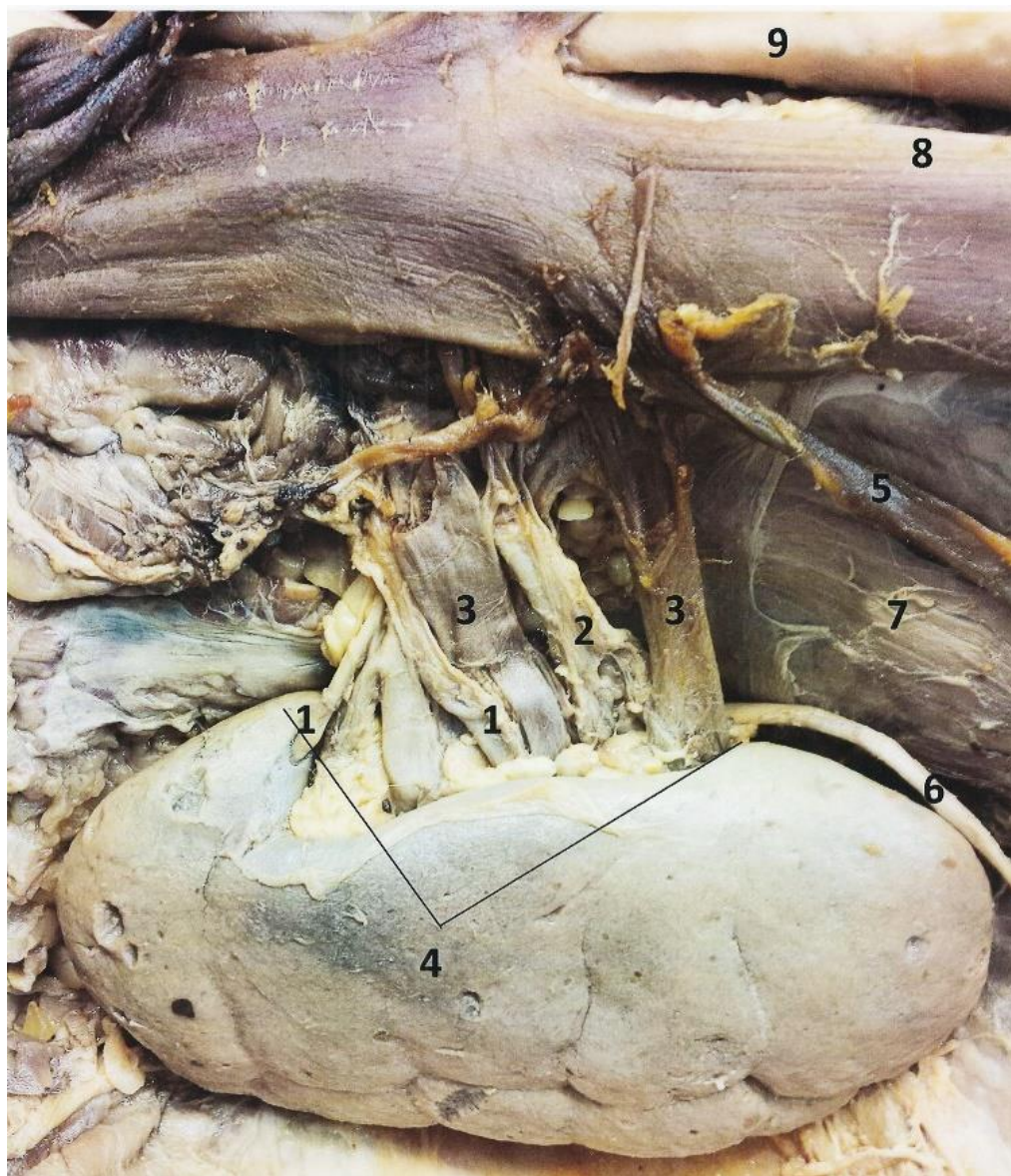
Redagavo: LSMU MF 5k, 20gr, Anatomijos instituto Prozektoriė Orinta Klimaitė

1. Arteriae renalis
2. Venae renalis
3. Ureter
4. Hilium renalis
5. Arteriae segmenti
6. Arteriae interlobular
7. Arteriae arcuata

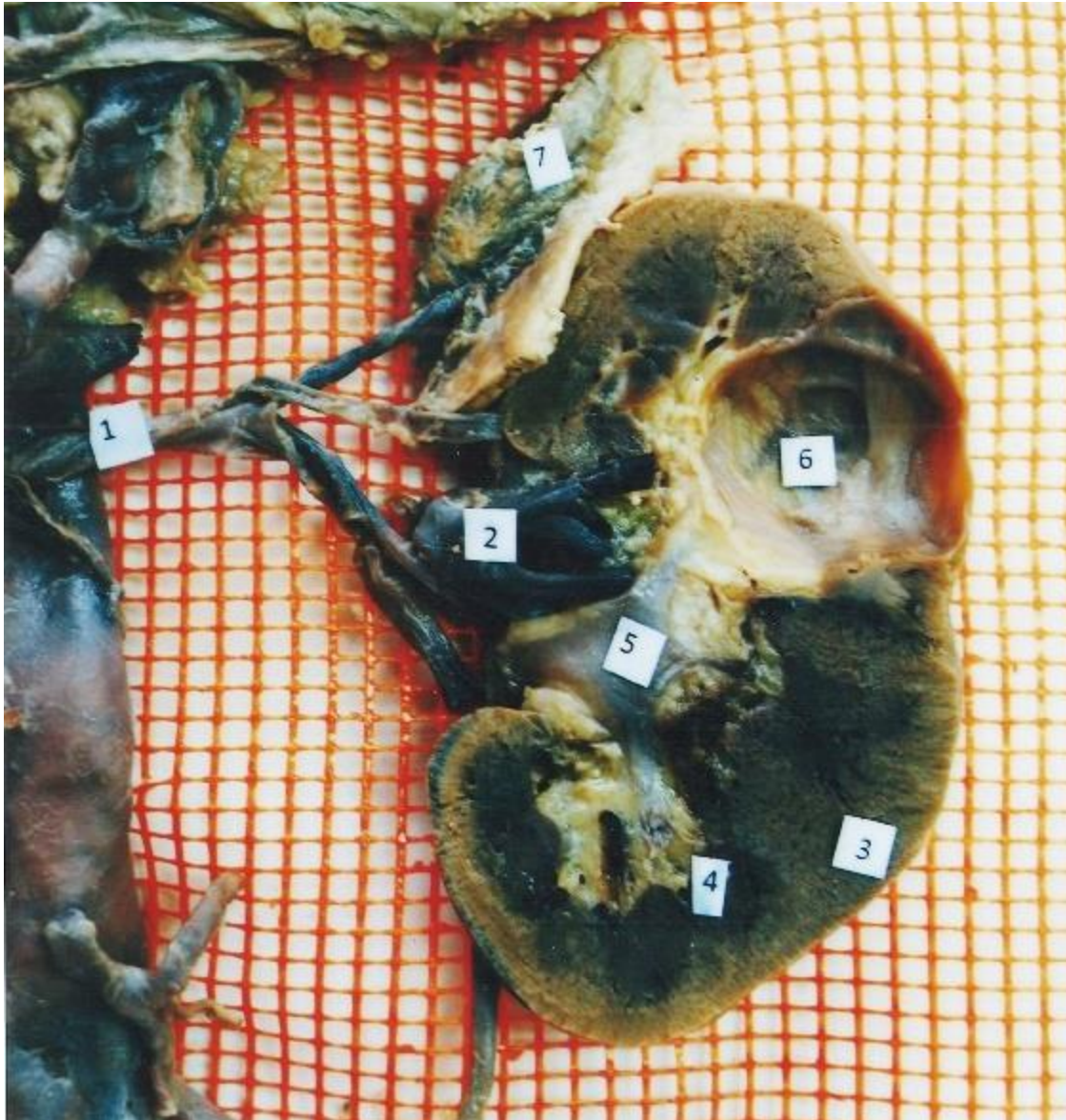

Redagavo: LSMU MF 5k, 20gr, Anatomijos instituto Prozektorė Orinta Klimaitė

1. A. renalis, r. posterior
2. A. renalis, r. anterior
3. Renalis
4. Hilum renale
5. V. testicularis
6. Ureter
7. M. psoas major
8. V. cava inferior
9. Pars abdominalis aortae



Darbą atliko: LSMU MF 8gr Rūta Pangonytė, Paulius Burkauskas, 2016m.  
 Redagavo: LSMU MF 5k, 20gr, Anatomijos instituto Prozektore Orinta Klimaitė



1. Vena renalis
2. A. renalis
3. Cortex renalis
4. Pyramis renalis
5. Pelvis renalis
6. Cista
7. Glandula suprarenalis

Redagavo: LSMU MF 5k, 20gr, Anatomijos instituto Prozektore Orinta Klimaitė