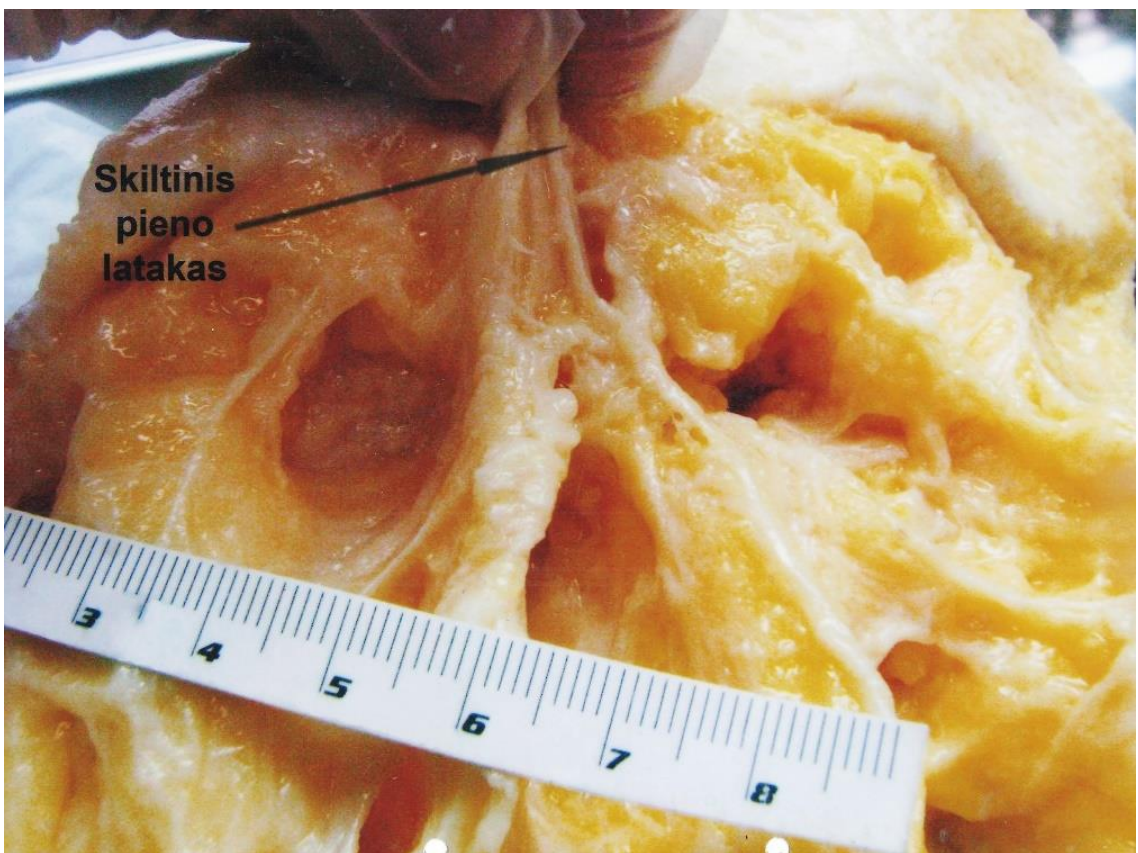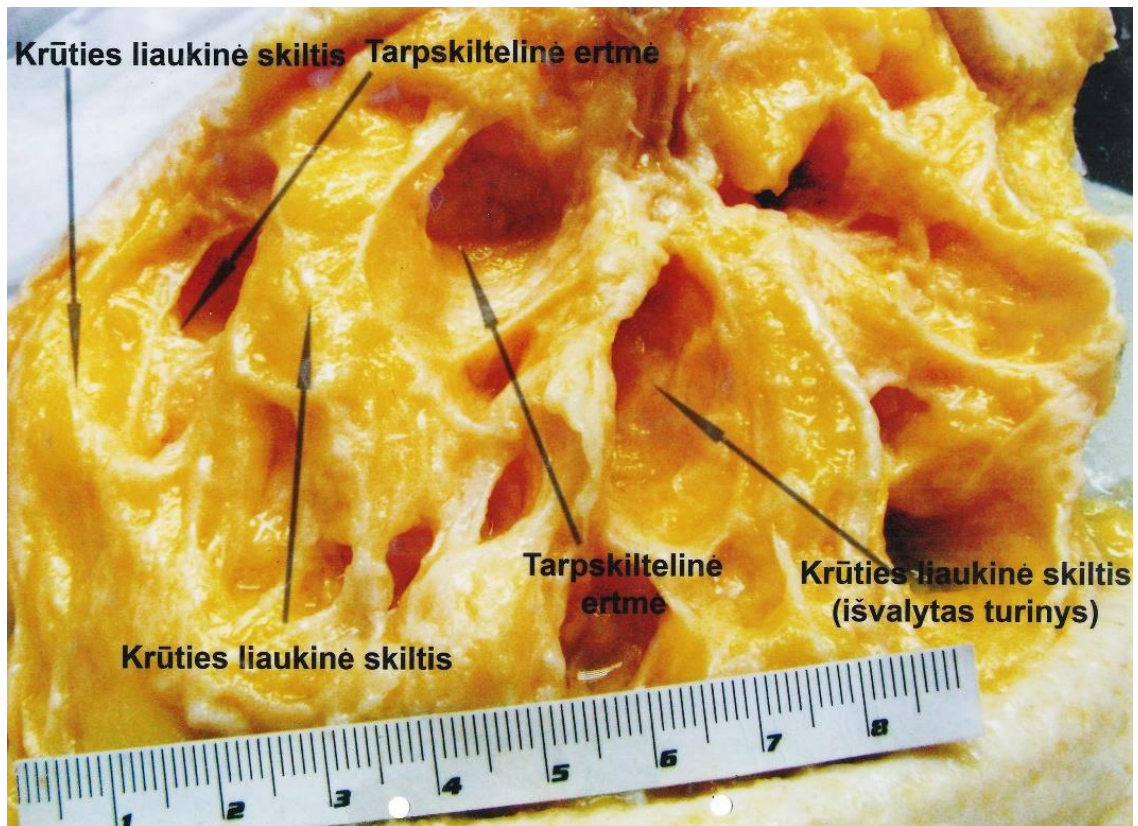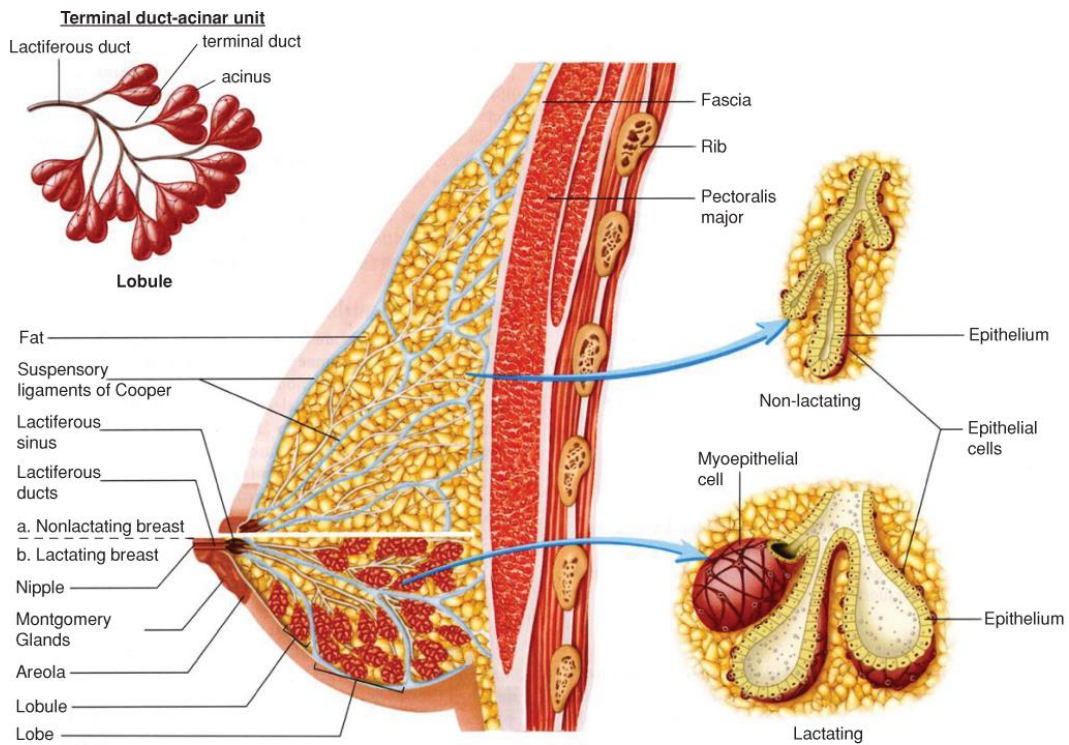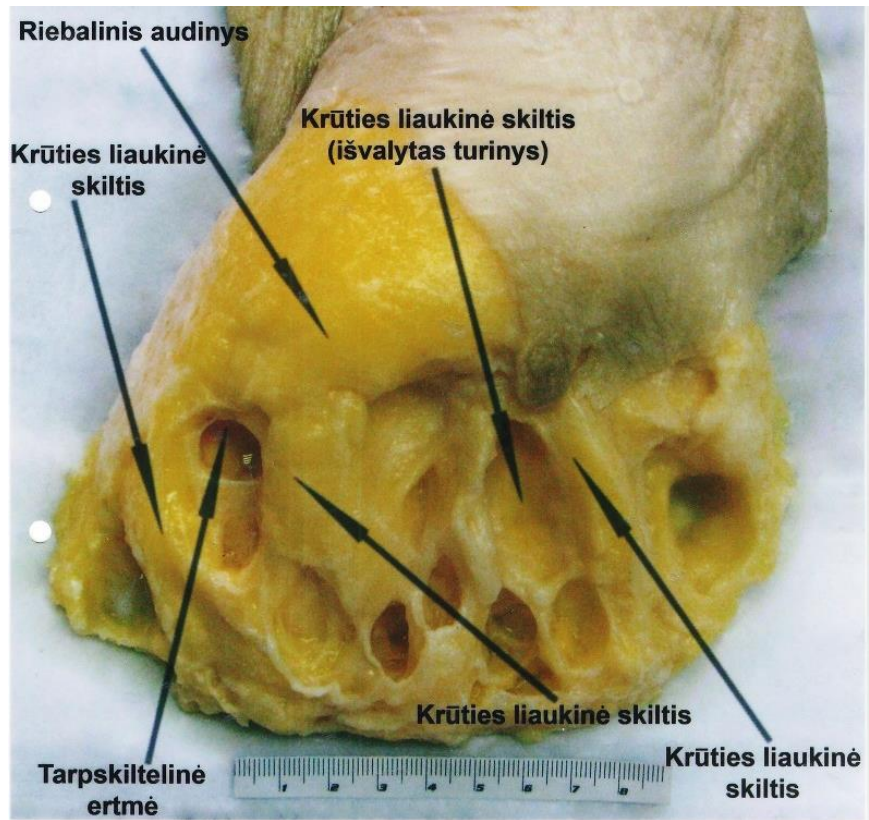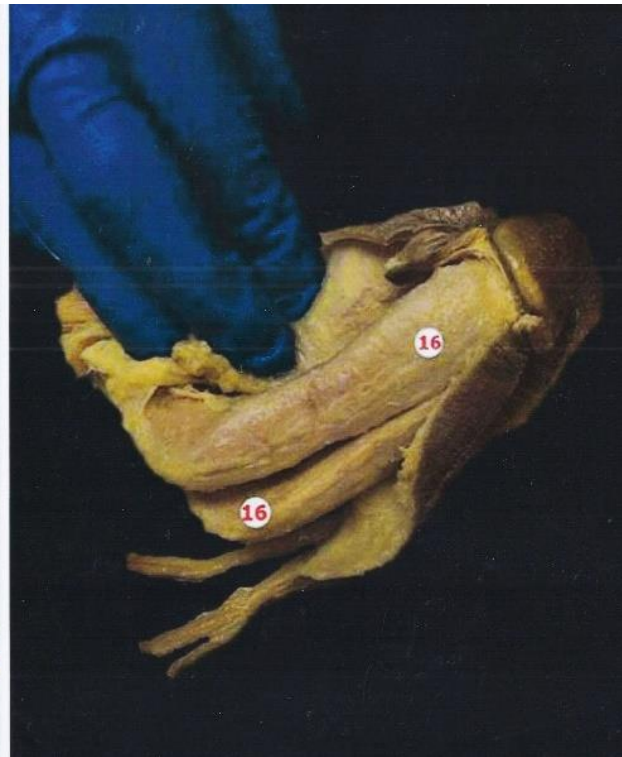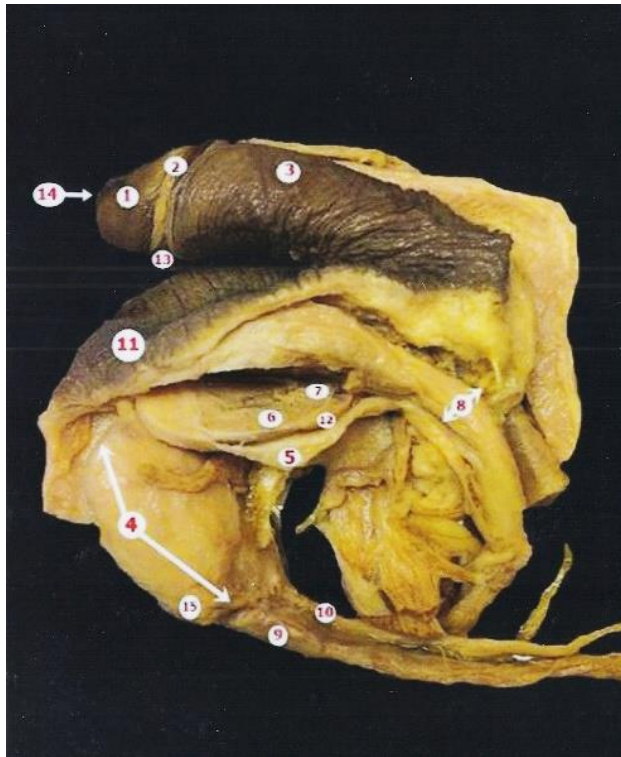


Source: Barbara L. Hoffman, John O. Schorge, Lisa M. Halvorson, Cherine A. Hamid, Marlene M. Corton, Joseph I. Schaffer: *Williams Gynecology*, 4th Edition
 Copyright © McGraw-Hill Education. All rights reserved.

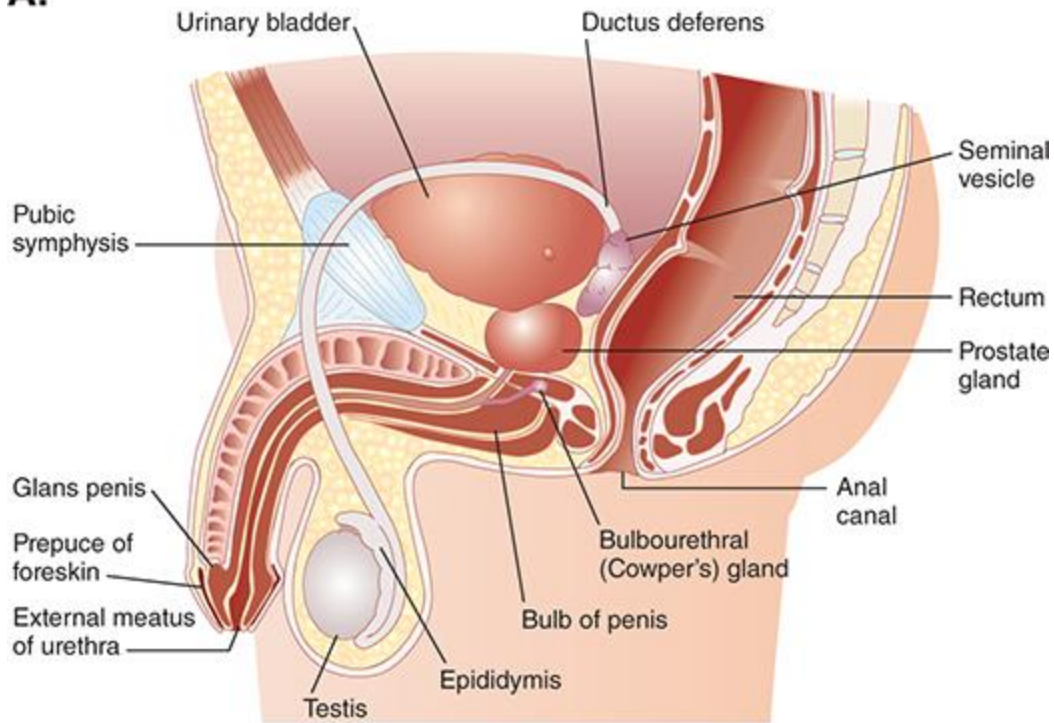
Redagavo: LSMU MF 5k, 20gr, Anatomijos instituto Prozetorė Orinta Klimaitė



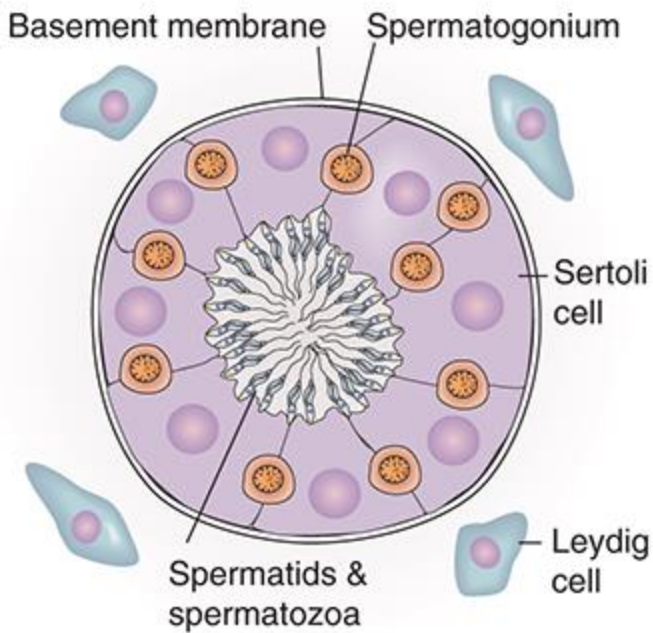
- | | |
|--------------------------------------|-----------------------------------|
| 1. Glans penis | 9. Ductus deferens |
| 2. Corona glandis | 10. Processus vaginalis peritonei |
| 3. Corpus penis | 11. Scrotum |
| 4. Testis | 12. Tunica albuginea |
| 5. Tunica vaginalis | 13. Frenulum |
| 6. Lobuli testis | 14. Ostium urethrae externus |
| 7. Rete testis in mediastinum testis | 15. Epididymis |
| 8. Funiculus spermaticus | 16. Corpus cavernosum penis |

Darbą atliko: LSMU MF 1k Eglė Radzevičiūtė 12gr, Kamilė Počepavičiūtė 3gr, 2016m.
 Redagavo: LSMU MF 5k, 20gr, Anatomijos instituto Prozektore Orinta Klimaitė

A.



B.



Source: Jonathan D. Kibble: *The Big Picture Physiology: Medical Course & Step 1 Review, 2e*
Copyright © McGraw Hill. All rights reserved.